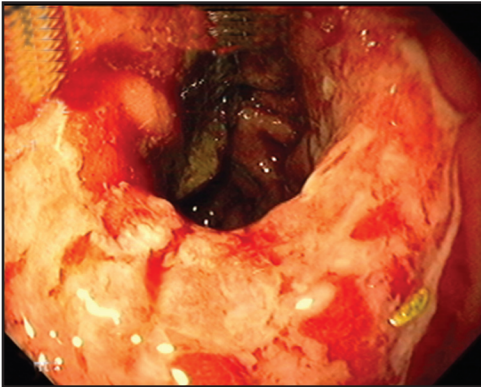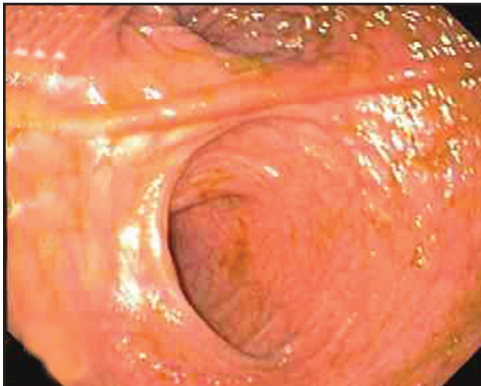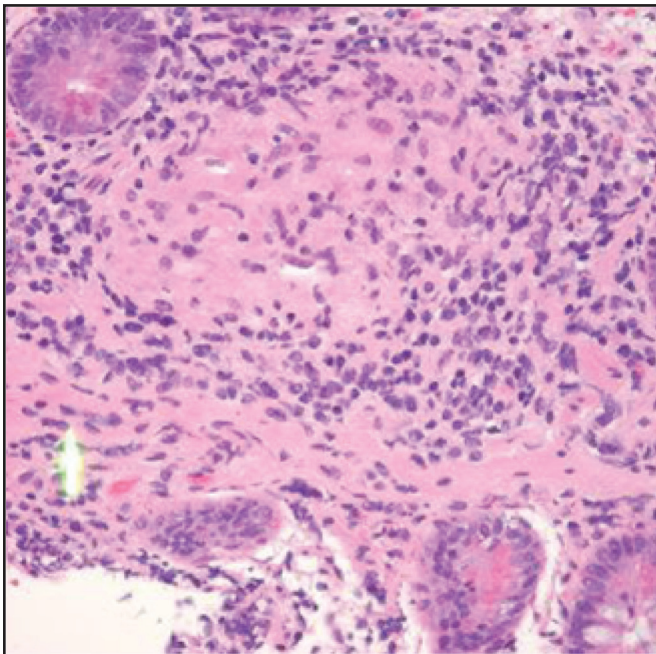


**Figure 55-1.** Ileal pouch in UC patient 6 months after IPAA.



**Figure 56-1.** Ileal pouch in UC patient 6 months after IPAA.



**Figure 57-1.** Biopsy from ileal pouch in patient 6 months after IPAA.